

OFFICE OF THE DISTRICT MEDICAL EXAMINER
DISTRICT 15 – STATE OF FLORIDA
PALM BEACH COUNTY
3126 GUN CLUB ROAD
WEST PALM BEACH, FLORIDA 33406-3005
(561) 688-4575
(561) 688-4592 FAX

NAME: BERNSTEIN, SIMON

CASE NUMBER: 12-0913

DATE OF DEATH: September 13, 2012

AGE: 76

SEX: M

RACE: W

DATE OF AUTOPSY: September 14, 2012 / 11:00 a.m.

AUTOPSY FINDINGS:

1. Acute subendocardial myocardial infarct.
2. Status post coronary artery bypass grafting, remote.
3. Severe calcific coronary atherosclerosis.
4. Focal myocardial fibrosis.
5. Bronchopneumonia.
6. Severe aortic atherosclerosis.
7. Fibrous pericarditis.
8. Calcific aortic valve annulus.
9. Nephrosclerosis.
10. Cirrhosis with chronic hepatitis.
11. Old splenic infarct.
12. Pleural effusions.
13. Sternum fracture.
14. Anterior rib fractures.
15. Osteoporosis.
16. Status post appendectomy, remote.
17. Status post cholecystectomy, remote.

NAME: BERNSTEIN, SIMON

CASE NUMBER: 12-0913

CAUSE OF DEATH: Myocardial infarct due to severe coronary atherosclerosis

CONTRIBUTORY CAUSE OF DEATH: Bronchopneumonia, cirrhosis

MANNER OF DEATH: Natural

OPINION: Simon Bernstein, a 76-year-old man, died from a heart attack due to blockage of the arteries that feed his heart. He also had pneumonia and cirrhosis. His blood hydrocodone concentration was therapeutic. There was no overdose. He did not have meningitis.



Michael D. Bell, M.D.
District Medical Examiner

Date Signed: November 8, 2012

MDB:df

NAME: BERNSTEIN, SIMON

CASE NUMBER: 12-0913

EXTERNAL EXAMINATION:

The body is that of a 5 foot 7 inch, 191 pound, overweight, white man who appears the reported age of 76 years. His body mass index is 29.9.

The body is well preserved and cold. Mild rigor mortis is detected in the extremities. Purple livor mortis is on his back.

The decedent is normocephalic without apparent injury to the face or scalp. The decedent has short, gray-brown hair. He has brown irides with no conjunctival petechiae. There is slight chemosis. The corneas are clear. The sclerae are nonicteric. No facial, nasal or mandibular fractures are palpated. The nasal septum is intact. No froth or fluid escapes from the nose or mouth. The teeth are natural and in good repair. There is no trauma of the lips, gums or frenulum.

The neck is symmetrical and has no trauma or injury. There is no palpable crepitus or hypermobility. No neck masses are observed.

The thorax is symmetric. The abdomen is protuberant with small ecchymoses on the abdomen. The external genitalia and anus are unremarkable. The decedent is circumcised.

The arms are symmetrical and normally developed. The arms have no needle tracks. The fingernails are short. The legs are symmetrical, and there is slight pedal edema. The back shows a symmetrical external contour and the spine is straight. The back has no trauma. The skin shows no rashes.

IDENTIFICATION:

No tattoos are on the body. A vertical 9 inch scar is in the midline of the chest. A vertical 10 inch scar is on the right abdomen. A transverse 3 inch scar is in the left groin. Three vertical scars run along the inside of the left leg, and they are 3 inches, 4 inches, and 18 inches, respectively.

The decedent is unclothed.

EVIDENCE OF MEDICAL INTERVENTION:

Two hospital blood tubes accompany the body, and they are dated 9/12/2012. The decedent has multiple needle punctures on the right and left antecubital fossa, lower arms and right hand, and all of them are surrounded by small ecchymoses. An identification band is on his right wrist.

NAME: BERNSTEIN, SIMON

CASE NUMBER: 12-0913

INTERNAL EXAMINATION:

BODY CAVITIES:

The sternum is fractured. Anterior ribs 2 through 6 are fractured bilaterally. There is a small amount of extravasated blood surrounding the fracture sites. There is extravasated blood in the anterior mediastinal soft tissues. The bones are osteoporotic, and the soft tissue is friable. There are no fractures of the clavicles, vertebral column or pelvis. The right and left pleural cavities each contain an estimated 200 to 300 milliliters of clear, straw-colored fluid. There is no blood within the peritoneal cavity. The pericardial cavity is obliterated by fibrous adhesions. The pericardial sac and diaphragm are intact. There are no fibrous or fibrinous adhesions involving the intestines. No aromatic or unusual odors are detected inside the body. The intravascular blood is liquid and clotted.

HEAD AND CENTRAL NERVOUS SYSTEM:

The scalp has no edema. The subgaleal tissues have no contusions or injuries. The temporal muscles have no contusions. The skull is intact and has no fractures. No epidural or subdural hematomas are present. The dura mater is intact and has no discoloration.

The 1400 gram brain has thin, transparent leptomeninges with no subarachnoid blood or exudate seen. The leptomeninges are not congested or hyperemic. The cerebral and cerebellar gyri and sulci are of normal size and configuration and have no edema or swelling. No cingulate, uncinata or cerebellar tonsil herniation is present. No contusions or defects are on the surface of the brain. The olfactory bulbs and rest of the cranial nerves are intact. The vertebral, basilar and cerebral arteries, including the arterial circle of Willis, have a moderate amount of atherosclerosis.

The cerebral hemispheres have a thin, gray, cortical ribbon with no slit-like or punctate hemorrhages. The subjacent white matter, including the centrum ovale and corpus callosum, has no discoloration, hematomas or masses. The lateral ventricles are enlarged but have normal configuration and contain no blood. The third ventricle is enlarged. The caudate and lenticular nuclei are unremarkable, as is the thalamus. The mammillary bodies have no discoloration or hemorrhage. The hippocampal gyri are symmetric and have no sclerosis. The occipital lobes are normal. The midbrain, pons and medulla oblongata are unremarkable. The folia cerebelli are neither atrophic nor swollen. The cerebellar white matter and deep midline nuclei are normal. The fourth ventricle and cerebral aqueduct are of normal size and contain no tumor, blood or exudate.

NECK:

The oropharynx is light red-yellow with no trauma or injuries. The epiglottis is light red-yellow and leaf-like, and there is a small amount of aryepiglottic edema. No food or foreign objects obstruct the oropharynx, larynx, trachea or bronchi. The hyoid bone and thyroid cartilages are intact. The anterior cervical neck strap muscles and soft tissues have no contusions or injuries. The prevertebral muscles, fascia and soft tissues have no contusions. The anterior cervical vertebral column is intact. The thyroid gland has its normal anatomic size and location. The thyroid gland is slightly nodular. The cervical lymph nodes are not enlarged.

CARDIOVASCULAR:

The 650 gram heart is covered by easily broken fibrous adhesions. No petechiae or contusions are on the epicardial surface. There is an increased amount of epicardial fat. The heart is right coronary artery dominant. The native coronary arteries arise normally from the aortic root, and their ostia are patent. The native coronary arteries have severe calcific coronary atherosclerosis. A stent is in the native right coronary artery. A clot is in this stent. The native left anterior descending coronary artery has 90-95% intraluminal narrowing by atherosclerosis. The native left circumflex coronary artery has 95% intraluminal narrowing by atherosclerosis. A left thoracic artery graft inserts in the left anterior descending coronary artery. This graft is patent. Two saphenous vein grafts arise from the ascending aorta. One inserts into the posterior descending coronary artery and the other into the left marginal coronary artery. The former saphenous vein graft is occluded at its ostium. The saphenous vein graft to the left marginal coronary artery is narrowed to a pinpoint at its ostium. A stent is in the proximal graft and beyond the stent distally the lumen is narrowed to a pinpoint again.

The free left ventricular wall, ventricular septum, and right ventricular wall are 1.8, 2.0, and 0.3 centimeters thick, respectively. The atria and right ventricles are dilated. The left ventricle chamber is 4 centimeters in diameter. The myocardium is red-brown and firm, with focal scarring in the posterior and lateral left ventricle walls. The scars are up to 1 centimeter in greatest dimension. The endocardium is smooth and transparent with a 1 centimeter area of endocardial thickening in the right ventricle. There is no endocardial hemorrhage or mural thrombosis.

The tricuspid, pulmonic, mitral and aortic valve circumferences are 12.9, 9.0, 11.0, and 7.0 centimeters, respectively. The valves have no ballooning, deformities or vegetations. The commissures are normal. The chordae tendineae are neither ruptured nor thickened. There is moderate calcification of the aortic valve annulus. The rest of the valves and annuli have no calcification.

The aorta has no trauma or injuries. The aorta has severe calcific and ulcerative atherosclerosis. There is no aortic dissection or aneurysm formation.

RESPIRATORY:

The right and left lungs weigh 1180 and 910 grams, respectively. The lungs are normally inflated and occupy most of the pleural cavities. Both lungs have smooth, glistening, transparent pleural surfaces, except for fibrous adhesions involving the posterior lateral left upper lobe. No anthracotic pigment is on the pleural surfaces. No depressions, nodules or bullae are seen. The lungs are light brown anteriorly and dark red posteriorly. The parenchyma has focal nodular areas of consolidation in the posterior segments of the lower lobes. The parenchyma exudes red fluid. No tumor, abscesses, granulomas or pulmonary thromboemboli are seen. The bronchial tree contains red fluid. The pulmonary arteries are normal. The hilar lymph nodes are normal.

NAME: BERNSTEIN, SIMON

CASE NUMBER: 12-0913

HEPATOBIILIARY SYSTEM:

The 1990 gram liver has an intact nodular capsule, and its normal parenchyma is replaced by 2 to 4 millimeter in diameter brown, cirrhotic nodules. No infarcts, granulomas or tumors are seen. The gallbladder is surgically absent.

HEMOLYMPHATIC SYSTEM:

The 340 gram spleen has a smooth, intact capsule with no trauma or injury. A 4 x 1 centimeter shrunken, yellow infarct is present. No granulomas or tumors are seen within the otherwise red-purple, firm parenchyma. Gray-white follicles are not identified.

ENDOCRINE SYSTEM:

The pancreas is pale brown, lobular and soft with no fat necrosis, extravasated blood, tumor or fibrosis. The adrenal glands are thin and have yellow cortices and gray-white medullae. No hemorrhage or tumor is seen in the adrenal glands.

GASTROINTESTINAL SYSTEM:

The esophagus is lined by a smooth, gray-white mucosa with no ulcers, tumors or esophageal varices. The stomach is intact and contains 150 milliliters of red fluid. No aromatic or unusual odors are detected. No pills, capsules or granular material are seen. No blood is in the stomach. The gastric mucosa is red-brown with normal rugae and no ulcers, polyps or tumors. The duodenum has no ulcers. The small and large bowel has no perforation, obstruction or infarction. No mass or tumor is seen in the gastrointestinal tract. The appendix is not identified.

UROGENITAL SYSTEM:

The right and left kidneys weigh 200 and 190 grams, respectively. Both kidneys are enlarged and have scarred, pitted and granular, red-brown surfaces. There is no trauma or injury to the kidneys. The cortices are reduced in thickness to 4 millimeters, and there is an indistinct corticomedullary junction. There are no infarcts, granulomas or tumor. There is no hydronephrosis or renal calculi. There is an increased amount of peripelvic fat. The ureters and bladder are normal. The bladder is intact but contains no urine.

NAME: BERNSTEIN, SIMON

CASE NUMBER: 12-0913

DATE: October 18, 2012

NUMBER OF SLIDES: 8

MICROSCOPIC EXAMINATION

HEART: Myocyte disarray and focal myocardial fibrosis. Myocyte hypertrophy. Acute subendocardial infarction with scant neutrophil infiltration.

LEFT CORONARY ARTERY: 90-95% intraluminal narrowing by atherosclerosis.

LEFT ANTERIOR DESCENDING CORONARY ARTERY: 90-95% intraluminal narrowing by atherosclerosis.

LUNGS: Bronchopneumonia. Rare fat emboli in pulmonary arteries.

LIVER: Cirrhosis with chronic hepatitis.

KIDNEY: Arteriosclerosis.

SPLEEN: Old infarct.

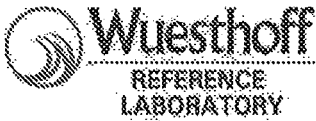LYMPH NODE: Unremarkable.



Michael D. Bell, M.D.
District Medical Examiner

Date Signed: 10/29/12

MDB:df



Wuesthoff Reference Laboratory

6800 Spyglass Court
Melbourne, Florida 32940
Julie Bell, M.D., Laboratory Director

Patient: BERNSTEIN, SIMON
Client Patient ID: 15-12-913
Physician: BELL, MICHAEL

Age: 76 **Sex:** M
Account#: 7230586
Client: DIST 15 MEDICAL EXAMINER

TOXICOLOGY

Specimen Collected :09/14/2012

Lab Order No: 21171453

Reg Date: 10/23/12

Test Name	Result	Units	Cutoff/Reporting Limits
-----------	--------	-------	-------------------------

VOLATILE PANEL - VOLP 98245

SPECIMEN TYPE

ANTEMORTEM BLOOD LABELED "BERNSTEIN, SIMON L" DATED 9/12/12 1035

ETHANOL	NONE DETECTED	g/dL	0.020
ACETONE	NONE DETECTED	mg/dL	7.5
METHANOL	NONE DETECTED	mg/dL	15.0
ISOPROPANOL	NONE DETECTED	mg/dL	15.0

Analysis by Gas Chromatography (GC) Headspace Injection

BLOOD DRUG SCREEN - BDSME 98216

SPECIMEN TYPE

ANTEMORTEM PLASMA LABELED "BERNSTEIN, SIMON L" DATED 9/12/12 @ 1035

GC/MS

Quantity Not Sufficient

LC/MS/MS

HYDROCODONE, ZOLPIDEM, ACETAMINOPHEN, CAFFEINE, CAFFEINE METABOLITE

BLOOD IMMUNOASSAY SCREEN

SPECIMEN TYPE

ANTEMORTEM BLOOD LABELED "BERNSTEIN, SIMON L" DATED 9/12/12 @ 1035

AMPHETAMINES	NEGATIVE	mg/L	0.100
BARBITURATES	NEGATIVE	mg/L	0.100
BENZODIAZEPINES	NEGATIVE	mg/L	0.050
BUPRENORPHINE	NEGATIVE	mg/L	0.001
CANNABINOIDS	NEGATIVE	mg/L	0.050
COCAINE METABOLITE	NEGATIVE	mg/L	0.100
FENTANYL	NEGATIVE	mg/L	0.001
METHADONE	NEGATIVE	mg/L	0.050
OPIATES	POSITIVE	mg/L	0.050
SALICYLATES	NEGATIVE	mg/L	50.0



Wuesthoff Reference Laboratory

6800 Spyglass Court
Melbourne, Florida 32940
Julie Bell, M.D., Laboratory Director

Patient: **BERNSTEIN, SIMON**
Client Patient ID: **15-12-913**
Physician: **BELL, MICHAEL**

Age: **76** Sex: **M**
Account#: **7230586**
Client: **DIST 15 MEDICAL EXAMINER**

TOXICOLOGY

Specimen Collected :09/14/2012

Lab Order No: 21171453

Reg Date: 10/23/12

Test Name	Result	Units	Cutoff/Reporting Limits
-----------	--------	-------	-------------------------

TRICYCLICS	NEGATIVE	mg/L	0.100
------------	----------	------	-------

ACETAMINOPHEN - ACMP 98203

SPECIMEN TYPE

ANTEMORTEM PLASMA LABELED "BERNSTEIN, SIMON L" DATED 9/12/12 @ 1035

ACETAMINOPHEN	16.3	mg/L	10
---------------	------	------	----

Therapeutic range:
10.0 - 20.0 mg/L

Analysis by Enzyme Immunoassay.

FREE OPIATES PANEL - OPPF 98182

SPECIMEN TYPE

ANTEMORTEM BLOOD LABELED "BERNSTEIN, SIMON L" DATED 9/12/12 @ 1035

CODEINE	NONE DETECTED	mg/L	0.025
MORPHINE	NONE DETECTED	mg/L	0.025
HYDROCODONE	0.094	mg/L	0.025
6-MONOACETYLMORPHINE	NONE DETECTED	mg/L	0.005
HYDROMORPHONE	NONE DETECTED	mg/L	0.025
OXYCODONE	NONE DETECTED	mg/L	0.025
OXYMORPHONE	NONE DETECTED	mg/L	0.025

Analysis by GC/MS

ZOLPIDEM - ZONMS 98621

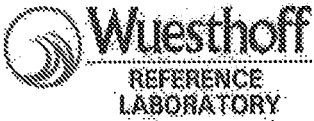SPECIMEN TYPE

ANTEMORTEM PLASMA LABELED "BERNSTEIN, SIMON L" DATED 9/12/12 @ 1035

ZOLPIDEM	NONE DETECTED	ng/mL	4.0
----------	---------------	-------	-----

Plasma concentrations following single oral 5 mg and 10 mg immediate release doses range from 29 - 110 ng/mL (mean, 59 ng/mL) and 58 - 270 ng/mL (mean, 120 ng/mL), respectively, occurring at a mean time of 1.6 hours. Peak plasma concentrations following a single oral 12.5 mg extended release dose ranged from 69 - 190 ng/mL (mean = 130 ng/mL) occurring at a mean time of 1.5 hrs.

The ratio of whole blood concentration to serum or plasma concentration in unknown for this analyte.



Wuesthoff Reference Laboratory

6800 Spyglass Court
Melbourne, Florida 32940
Julie Bell, M.D., Laboratory Director

Patient: **BERNSTEIN, SIMON**
Client Patient ID: **15-12-913**
Physician: **BELL, MICHAEL**

Age: **76** Sex: **M**
Account#: **7230586**
Client: **DIST 15 MEDICAL EXAMINER**

TOXICOLOGY

Specimen Collected :09/14/2012

Lab Order No: 21171453

Reg Date: 10/23/12

Test Name	Result	Units	Cutoff/Reporting Limits
-----------	--------	-------	-------------------------

Testing performed by NMS Labs, 3701 Welsh Rd, Willow Grove, PA 19090-2910


Specimens were intact upon receipt. Chain of custody, specimen security and integrity has been maintained. Testing has been performed as requested

Reviewed by: *Susan Rade* Date: 10-23-12

FINAL REPORT - THIS COMPLETES REPORTING ON THIS CASE

TOXICOLOGY_REPORT

BERNSTEIN, SIMON



Palm Beach County Medical Examiner's Office

Name: Simon Bernstein

Case Number: 12-0913

Prepared By: Heron Ruiz, Forensic Investigator

On Thursday, September 13, 2012 at about 8:15 a.m., Ted Bernstein called the Palm Beach County Medical Examiner's Office to request an autopsy on his father, Simon Bernstein, whom he said died at Delray Medical Center earlier in the morning. He said that his father is 76 years old with a history of Hepatitis, heart disease with previous open heart surgery and stents and hypertension. His father was admitted to the hospital.

I told Mr. Bernstein that the Medical Examiner would not assume jurisdiction of this case because the death did not appear to be due to anything other than natural causes. He then said that he was requesting an autopsy because after talking to his father's personal assistant, he believed that his father's younger girlfriend may have overdosed his father.

I told Mr. Bernstein to contact the appropriate law enforcement agency and to report the case.

At 9:00 a.m., Sergeant Matthew Castelli (ID: 6382) of the Palm Beach County Sheriff's Office called the Palm Beach County Medical Examiner's Office to report the case. He said that he contacted the Palm Beach County Sheriff's Office Violent Crimes Division (VCD) and that they declined to assign a Detective to this case. He said that Deputy Vince Haugh would complete a report. I told him to fax a copy of the report to the Palm Beach County Medical Examiner's Office. I told him also to have the hospital fax Mr. Bernstein's medical records to the Palm Beach County Medical Examiner's Office for review and to have the body placed in the hospital morgue.

I received the medical records from the hospital. The records state that on September 12, 2012, shortly after 10:00 a.m., Mr. Bernstein arrived at the hospital Emergency Room. He was alert and able to communicate. He reported that he suffered from fibromyalgia being treated with Prednisone. He complained of generalized weakness and dizziness since September 7, 2012. His family said that he was disoriented and that he collapsed while trying to get up. The hospital staff diagnosed him with a Myocardial Infarction and congestive heart failure.

I discussed the case with Chief Medical Examiner, Dr. Michael Bell. He told me that have the body transported to the Palm Beach County Medical Examiner's Office for further review. I contacted Mr. Bernstein and told him that the medical examiner would do an autopsy on his father's body. I instructed him to arrange services with a funeral for release of the body.

I dispatched Elite Body Removal Service to the hospital on September 14, 2012 at 8:40 a.m.

Deputy Vince Haugh sent a report to the Palm Beach County Medical Examiner. The report states that on September 13, 2012 he went to Mr. Bernstein's (decedent) home at 7020 Lions Head Lane, Boca Raton, Florida, 33496. He met with Ted Bernstein. Ted told him that his father, Simon Bernstein was taken to Delray Medical Center at about 10:00 a.m., September 12, 2012 and that he died in the early morning, September 13, 2012. He said his father's caretaker, Rachel Walker told him that his father's girlfriend, Maritz Puccio might have given his father a larger than prescribed dose of Hydrocodone and an Ambien. Ted voiced his concern at the hospital and the doctors told him that they did not suspect foul play in this case and that they would not request an autopsy.

Ms. Walker reported that the decedent suffered from Polymyalgia, Hepatitis C and had open heart surgery. The decedent recently started taking Prednisone, which affected his mental stability. She said that she found the decedent on the couch when she arrived at his home on September 12, 2012 at about 8:30 a.m. Ms. Puccio arrived home a short while later and apparently there was some disagreement on whether they should take him to the hospital. Ms. Walker ultimately decided to take him to the hospital. Ms. Walker said that the decedent received a prescription of 100 Hydrocodone pills on September 7, 2012 and that she believed that Ms. Puccio was giving him more than the prescribed doses. Ms. Walker said that she believed there were only about 30 pills left in the bottle. Deputy Haugh counted the pills and found 90.5 remaining in the bottle. He concluded that the decedent was most likely not being over medicated.

Deputy Haugh talked to Mr. Bernstein's other son, Eliot Bernstein. Eliot reported that he was out to dinner with his father and Ms. Puccio on September 8, 2012 and that his father asked Ms. Puccio for one of her Ambien's to help him sleep. Ms. Puccio refused to give him the Ambien leading to a brief argument.

Deputy Haugh collected Mr. Bernstein's medications>

1. Prednisone (5mg), 2 times daily
2. Benicar (20mg), 1 daily
3. Cartia (180mg), 2 times daily
4. Clopidogrel (75mg), 1 time daily
5. Isoborbide Mononitrate (30mg), 2 times daily
6. Pantopravole (40mg), 1 time daily
7. Ranexa (500mg), 2 times daily
8. Bayer aspirin (81mg)
9. Q-var (40mg) puff two daily
10. Serevant (1 puff), two times daily
11. Lyrica (50mg), 1 time daily
12. Vitamin D (D3), 1 daily
13. Homocysteine Formula (b625mg), folic acid

Nothing Further at this time